CT Evaluation of Acute Enteritis and Colitis: Is It Infectious, Inflammatory, or Ischemic?[1]

Brandon C. Childers, MD
Sarah Wallace Cater, MD
Karen M. Horton, MD
Elliot K. Fishman, MD
Pamela T. Johnson, MD

RadioGraphics 2015; 35:1940–1941

Published online 10.1148/rg.2015150125

Content Codes: CT ER GI

[1]From the Russell H. Morgan Department of Radiology and Radiological Science, Johns Hopkins Hospital, 601 N Caroline St, Room 4223, Baltimore, MD 21287. Presented as an education exhibit at the 2014 RSNA Annual Meeting. Received April 20, 2015; revision requested July 16 and received August 7; accepted August 19. All authors have disclosed no relevant relationships. **Address correspondence to** P.T.J. (e-mail: *pjohnso5@jhmi.edu*).

The full digital presentation is available online.

Colitis and enteritis are common causes of abdominal pain. Their differential diagnosis is broad, including infectious causes such as pseudomembranous colitis or *Salmonella* species, inflammatory causes (Crohn disease or ulcerative colitis), and ischemia. Each cause has a substantially different management strategy, which makes appropriate radiologic identification crucial. Although definitive diagnosis often relies on endoscopic biopsy results, stool culture results, or other clinical features, it is the job of the radiologist to help guide the diagnosis. The full online presentation reviews the multidetector computed tomographic (CT) appearance of infectious, inflammatory, and ischemic forms of acute enteritis and colitis and is aimed at the radiologist in training. For each cause, both general and specific multidetector CT findings in the small bowel and colon are discussed. Added focus is placed on distribution patterns and extraintestinal findings that can act as important diagnostic clues.

Infectious enterocolitis is due to bowel inflammation caused by bacteria, viruses, or parasites. A key radiologic feature of infectious enterocolitis is the distribution of inflammation produced by the offending organism. For small bowel infections, parasitic enteritis caused by *Giardia* and *Strongyloides* species most often involves the proximal small bowel, whereas bacteria such as *Salmonella*, *Shigella*, and *Yersinia* species affect the distal small bowel. Tuberculosis, typhlitis, and amebiasis most frequently involve the distal ileum and cecum. In the colon, *Yersinia* and *Salmonella* species frequently infect the ascending portion, whereas *Shigella* species infects the descending colon. Pancolitis can be seen with *Clostridium difficile*, cytomegalovirus, and *Escherichia coli*. A relatively specific CT finding is the accordion sign associated with *C difficile* (Fig 1).

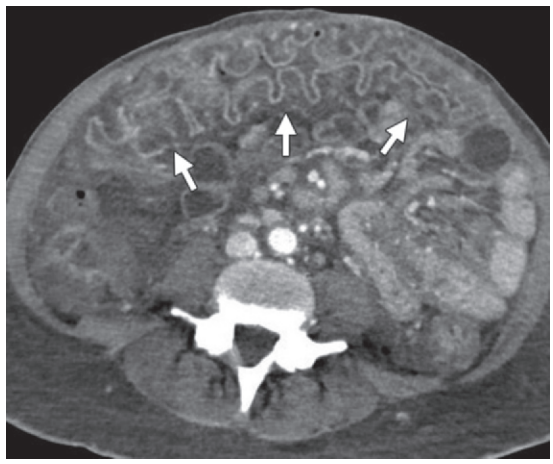

Figure 1. Pseudomembranous colitis secondary to *C difficile* overgrowth in a 36-year-old woman. Axial image from intravenous contrast material–enhanced multidetector CT depicts edematous hypoenhancing mural and haustral thickening, with mucosal enhancement indicative of the thumbprinting and accordion signs (arrows).

TEACHING POINTS

- Characteristic intestinal and extraintestinal CT findings are associated with each cause of acute enteritis and colitis.
- An optimized CT protocol is key to identification of diagnostic features.
- Infectious enterocolitis typically follows a geographic distribution depending on the organism responsible.
- Ulcerative colitis and Crohn disease differ in distribution and in radiographic manifestations.
- Ischemic enteritis and colitis have a highly variable appearance depending on the cause and chronicity of bowel ischemia.

Inflammatory enterocolitis can be primary (inflammatory bowel disease, vasculitis) or secondary (chemotherapy, radiation therapy, graft versus host disease, and angiotensin-converting enzyme inhibitor–induced enteritis). Two common forms of inflammatory bowel disease are ulcerative colitis and Crohn disease. Ulcerative colitis always involves the rectum and a variable amount of colon, whereas Crohn disease typically involves the distal ileum. At CT, the mural thickening in Crohn disease can be greater than 1 cm (11–13 mm). The morphology is typically eccentric (Fig 2), and distribution is characteristically segmental. In contradistinction, the inflamed wall in ulcerative colitis is typically not as thick (approximately 8 mm), with concentric morphology and a continuous pattern of distribution. Acute inflammation in the setting of Crohn disease often results in a mesenteric comb sign at CT, due to hyperemia and engorgement of the vasa recta. With ulcerative colitis, perirectal fibrofatty proliferation is a common CT finding for patients with chronic inflammation. Extraintestinal manifestations such as abscesses and fistulas are characteristic of Crohn disease, secondary to transmural inflammation, as opposed to ulcerative colitis.

Ischemic colitis and enteritis can result from arterial compromise, venous insufficiency, or low flow states that globally reduce perfusion. The CT appearance of ischemic enterocolitis varies depending on the cause and the time of onset relative to patient presentation and imaging. For example, arterial occlusion manifests as a thin bowel wall in the intermediate stage; in cases due to venous insufficiency, wall thickening with hyperattenuating mucosa and submucosal edema occurs during the intermediate phase. The online presentation explores CT findings of colitis and enteritis.

Figure 2. Crohn disease in a 16-year-old girl. Coronal multiplanar reconstruction from intravenous contrast-enhanced CT shows mural thickening and enhancement of the terminal ileum (white arrows). The mesenteric comb sign (black arrows) is also noted owing to increased blood flow on the mesenteric side of the involved small bowel and perivascular inflammation.

Acknowledgment.—We thank Hannah Ahn for creating the graphic art in slides 10 and 13 of the online presentation.

Suggested Readings

Barral M, Boudiaf M, Dohan A, et al. MDCT of acute colitis in adults: an update in current imaging features. Diagn Interv Imaging 2015;96(2):133–149.

Philpotts LE, Heiken JP, Westcott MA, Gore RM. Colitis: use of CT findings in differential diagnosis. Radiology 1994;190(2):445–449.

Romano S, Lassandro F, Scaglione M, Romano L, Rotondo A, Grassi R. Ischemia and infarction of the small bowel and colon: spectrum of imaging findings. Abdom Imaging 2006;31(3):277–292.